Prevention, Diagnosis and Treatment of Peri-implant Disease
Canadian Academy of Periodontology – 62nd Annual Meeting
Ottawa, Canada - May 27th, 2017

Munib Derhalli BSc, ***DMD, MBA, MSc,***
Diplomate of the American Board of Periodontology

Osseointegration

- Direct contact of bone and implant at the light microscope level
- Never occurs on 100% of the implant surface (usually between 30% and 95%)
- Remodeling of bone occurs constantly as part of the normal physiology of bone and continues to occur after the implant has been placed

Attachment Mechanism (Biologic Width)

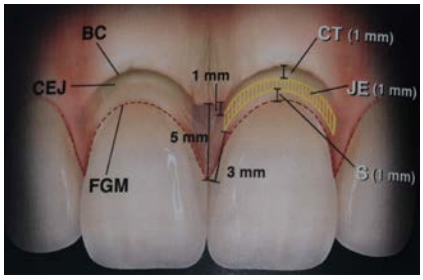

Implant vs. Natural Tooth

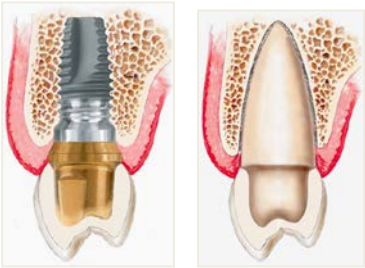

Attachment Mechanism

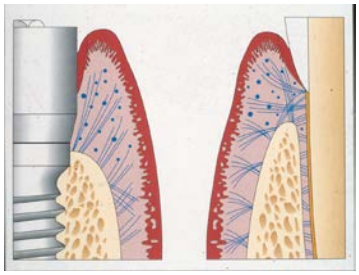

Initial Patient Assessment

Mobility – Implants have no PDL therefore there should be no mobility (check healing abutment)

Plaque Index – Determine if all plaque and calculus is removed from abutments without creating a rough surface which may harbor bacteria

Peri-Implant Tissue Health - Clinical signs such as color, consistency, contour should be noted – which may indicate an adverse reaction in the tissues surrounding the implant

Probing – Controversial – need to establish a baseline and definitely probe if inflammation present

Bleeding – As the only sign may not be an indication of histological changes (remember the attachment mechanism)
Radiographs – One of the most important parameters for determining success of the implant. Can reflect bone volume, density as well as the functional relationship between the implant, prosthesis, and implant-abutment components

Encode Technology (refer to Compendium article –Dr. Derhalli)

Immediate Implant Placement with Temporization - Healing of Extraction Sockets
Natural Teeth Extracted Using Flap Elevation

1. Mean Vertical Bone Loss – 1.24 mm (0.9 – to 3.6 mm)
2. Mean Horizontal Bone Loss – 3.79 mm (2.46 to 4.56 mm)
3. Socket Remodeling Occurs by 6 Months of Healing

Immediate Implant Placement with Temporization
Studies show that size of the horizontal bone gap is an important determinant with respect to predictability of spontaneous bone fill.

1. *The critical gap size that allows spontaneous healing without allografts, xenografts and barriers when implants are submerged in humans is typically < 2 mm but have been reported by Tarnow and Chu (single case report) to be 4 mm wide with no graft and allowed to heal by secondary intention.*
2. *Several studies have shown augmentation procedures at the time of implant placement reduced horizontal bone resorption but not crestal bone loss.*

Immediate Implant Placement with Temporization
Buccal plate thickness affects the degree of buccal plate resorption after immediate implant placement

1. If the buccal plate thickness is not between 1-2 mm, hard tissue augmentation is recommended. Grafting will result in crestal bone loss but the horizontal width (contour) will be maintained better
2. Studies have shown approximately 33% of patients manifested gingival recession on the buccal aspect (approximately 1 mm) after immediate implant placement (1 mm recession was also noted with CT grafts)
3. The implant should be placed 1-2 mm subcrestally to account for crestal bone resorption which can also be impacted through platform switching (Biologic Width Implications which impacts long-term continuing care guidelines)

Immediate Implant Placement with Temporization – Clinical Cases

External root resorption (Cervical Resorption Classifications – Refer to Compendium-Dr. Derhalli)

Peri-Implant Disease - Diagnosis

1. Peri-Implant Mucositis - similar to Gingivitis

- *No keratinized tissue present*
- *Inflammatory reaction in the tissues*
- *Pre-cursor to Peri-Implantitis*
- *Formation of Biofilm on implant surface*
- *Reversible – if identified early on (not associated with bone loss)*

2. Peri-Implantitis - similar to Periodontitis

- *Keratinized tissue may/may not be present*
- *Inflammatory reaction in the tissues*
- *Early, Established and Advanced Lesions*
- *Apply to all implants with radiographic and clinical bone loss exceeding that of normal bone loss (Implant success criteria – 1.5 mm bone loss year 1)*

Classification of Peri-Implantitis

Early

PD ≥ 4 mm (bleeding and/or suppuration on probing – 2 sides) Bone loss < 25% of the implant length

Moderate

PD ≥ 6 mm (bleeding and/or suppuration on probing – 2 sides) Bone loss 25% to 50% of the implant length

Advanced

PD ≥ 8 mm (bleeding and/or suppuration on probing – 2 sides) Bone loss > 50% of the implant length

Patient Assessment - Clinical and Radiographic Evaluation

Mobility – Implants have no PDL therefore there should be no mobility (check healing abutment/prosthetic abutment – hex wrench in Pt. set-up or available)
Plaque Index – Determine if all plaque and calculus is removed from abutments which may harbor bacteria – use to determine SPT frequency
Peri-Implant Tissue Health (BOP – Suppuration) Clinical signs such as color, consistency, and contour should be noted which may indicate an adverse reaction in the tissues surrounding the implant
Probing – Controversial – need to establish a baseline and definitely probe if inflammation present – Plastic - UNC probe not > .25 N pressure or a PCP 11 probe with .4 mm tip diameter
Bleeding (BOP) – As the only sign may not be an indication of histological changes (remember the attachment mechanism) wait 15 sec following light probing

Radiographs – One of the most important parameters for determining success of the implant. Can reflect bone volume, density as well as the functional relationship between the implant, prosthesis, and implant-abutment components (*take at implant placement, prosthesis placement, Implant Maintenance Appointments then annually)*

Patient Assessment – Hygiene Recall

- *Radiographic Evaluation*
- *Overall Clinical Assessment*

Long-Term Maintenance Considerations

Mucogingival Considerations – Tissue Biotype

- Clinical cases

Implant Complications – Surgical Repair

- Clinical Cases

Implant Maintenance – SPT - Homecare Considerations

The American Academy of Implant Dentistry has Estimated that over 3 Million Implants are now in Place in the United States and Estimated 500,000 new Implants are Being Placed Every Year

1. ***Implant Trends*** - Substantial increases in the number of dental implants being placed will result in more adverse events: Fx of the Implant Body, Fx of the retention screw, Fx of the Porcelain and the incidence of per-Implant Disease
2. ***Smoking*** – Exhibit higher rates of failure, Higher rate of Peri-implantitis and a decreased response to therapy when treating Peri-Implantitis
   (Rodriguez-Agueta OF, Figueiredo R, Valmageda-Castellon E, Gay-Escoda C. Postoperative complications in smoking patients treated with Implants J. Oral Maxillofac Surg 2011;69:2152-2157)
3. ***Implant success criteria to be familiar with*:** (First year following implant placement expect approximately 1.5 mm of bone loss (annual radiographs are essential)
4. ***Cost*** – The cost of maintaining dental implants over time was five times greater than the cost associated with maintaining natural teeth
   (Atieh MA, Alsabeeba NH, Fagion CM, Duncan WJ. The frequency of peri-implant diseases: a systematic review and meta-analysis J. Perio 2013;84:1586-1598)

Long-Term Maintenance Considerations
Implant Maintenance

Implant Hex Wrench (fits coverscrew and Healing Abutment)-Bubble Rule

Implant Surface Characteristics/Topography - Allow for Minor Surface Changes Caused by Common Instrumentation Methods
(Esposito M, Lausmaa J., Hirsch JM, et al. Surface Analysis of Failed Oral Titanium Implants J. Biomed Mater Res. 1999;48:559-568)
Instrumentation – Hand or ultrasonic instrumentation should be oriented parallel to the long-axis of the implant surface: Plastic, Metal (use with caution), Graphite, and Gold Tips. The preventive Benefits of Biofilm removal outweigh the slight surface alterations due to proper technique
Radiographs – Detect Bone Level (comparison) and residual cement which can act as a vehicle for Biofilm retention– Peri-implant mucositis can be detected at about 6 weeks post restoration placement. Radiographs should be taken at Implant placement, Crown placement, and annually thereafter
Clinical Evaluation – Peri-Implant disease characteristic include Marginal Erythema, BOP, Exudate, Saucer shaped circumferential bone defect
Probing – Should be oriented as parallel as possible to the implant body and measurements should be recorded at all 6 probing sites (UNC Probe)

Long-Term Maintenance Considerations - Implant Maintenance – (Hygiene Recall)

Peri-Implant Mucositis is similar to Gingivitis and Peri-Implantitis is similar to Periodontitis

Prevention of Peri-Mucositis – Every effort should be made to prevent Peri-Implant Mucositis. Patients should be screened appropriately for risk factors. Need to resolve pre-existing periodontal disease before implant placement.
Plaque Control - Establish criteria that monitor implant health and determine inflammatory complications as part of an ongoing periodontal maintenance program. Customize oral hygiene regimens to reflect the type of restoration taking into considerations contour and accessibility. Record Plaque index at each visit.
Recall Frequency – Dependent upon the severity of the Peri-implant disease - More frequent recall visits may be indicated – different from natural teeth – attachment mechanism. Determine level of frequency based on biofilm formation and modify the regiment 3-4 x a year may be indicated

Implant Maintenance Brochure

Page 1

Page II

Encode Technology – refer to Compendium article – Dr. Derhalli

iTero Scanner
Electronic Impression Device
Active Scanning Technology

THANK YOU

Munib Derhalli DMD, MS, MBA
Diplomate of the American Board of Periodontology
drderhalli@aol.com